

**PATIENT PRESENTING CLINICAL SIGNS**

French Fry Vandusen History: 1-week duration of vomiting.

**SPECIES** Physical Examination: N/A.

Canine Urinalysis: N/A.

CBC: N/A.

**BREED** Serum Biochemistry: N/A.

Miniature Schnauzer Radiographic Findings: Non-mobile mineralized foreign material in the pyloric antrum.

**SEX**

MN

**Age**

8 years

**ULTRASONOGRAPHIC EXAMINATION OF THE ABDOMEN**

**Urinary System**

Full urinary bladder with a normal thickness and appearance of the wall. Normal anechoic urine with no sediment or uroliths evident.

**WEIGHT** Normal trigone area, proximal urethra (0.6 cm), and iliac blood vessels.

Normal iliac lymph nodes (0.9 cm). Ureters not visualized.

Normal renal size (left 4.5, right 4.7 cm), echogenic appearance, cortico-medullary differentiation, pelvis and capsule.

**INTERPRETED BY**

Remo Lobetti, BVSc,  
 MMedVet (Med), PhD, Dipl.  
 ECVIM

**Reproductive System**

Small hypoechoic prostate (1 cm).

**IMAGING PERFORMED BY**

Sonya Myers, DVM

**Adrenal Glands**

Normal shape, echogenic appearance, size, and position. Left 0.37/0.41 cm, right 0.51/0.38 cm.

**HOSPITAL NAME**

Oviedo Veterinary Care and  
 Emergency

**Spleen**

Normal size (2.1 cm) and echogenic appearance. Smooth homogenous parenchyma, regular curvilinear capsule, and normal vasculature. No evidence of inflammatory, neoplastic, infarction, or infiltrative changes noted.

**REFERRING VET**

Dr Kim

**Liver**

Normal size, echogenic appearance, portal markings, and regular curvilinear capsule. No nodules or masses evident. Full gall bladder containing normal anechoic bile. Normal thickness and appearance of the gall bladder wall. Normal bile duct (0.2 cm).

**INVOICE**

303172

**Gastrointestinal**

**DATE**

8/5/22

Fluid distended stomach with normal appearance of the wall. Shadowing jejunal foreign body (4.3 cm) with thickening of the wall (0.55 cm) associated with the foreign body but with no loss of layering. Fluid/chyle distended intestine proximal to the obstruction. Normal appearance of the rest of the small intestine, ileo-cecal junction, and colon with no loss of layering, normal wall thickness and peristaltic activity, and no distension of the lumen.


**PATIENT** *Pancreas*

French Fry Vandusen

Normal size (1.3 cm) and echogenic appearance. Regular capsule. Normal echogenic appearance of the mesentery and fat surrounding the pancreas.

**SPECIES** *Free Abdomen*

Canine

Mesenteric lymphadenomegaly (0.7 x 1.4 cm) with normal shape and echogenic appearance. Hyperechogenic appearance of the mesentery in the region of the intestinal obstruction. Small amount of ascites.

**BREED**

Miniature Schnauzer

**SEX** **ULTRASONOGRAPHIC FINDINGS**

MN

Primary Findings:

**Age**

8 years

- Small intestinal foreign body.
- Ascites.
- Mesenteric inflammation

**WEIGHT**

Secondary Findings:

- None.

**INTERPRETED BY**

 Remo Lobetti, BVSc,  
 MMedVet (Med), PhD, Dipl.  
 ECVIM

**INTERPRETATION OF THE FINDINGS & FURTHER RECOMMENDATIONS**

The appearance of the small intestine is consistent with an intestinal obstruction and with the lymphadenomegaly, mesenteric inflammation and ascites, perforation would be an important consideration.

**IMAGING PERFORMED BY**

Sonya Myers, DVM

Although the thickening of the jejunum is most likely from the foreign body, underlying inflammatory bowel disease, dietary hypersensitivity, and granulomatous enteritis needs to be considered,

**HOSPITAL NAME**

Further assessment/therapy would be laparotomy with biopsy of the GI tract

 Oviedo Veterinary Care and  
 Emergency

**REFERRING VET**

Dr Kim

**INVOICE**

303172

**DATE**

8/5/22



**PATIENT IMAGES**

French Fry Vandusen **Jejunum**

**SPECIES**

Canine

**BREED**

Miniature Schnauzer

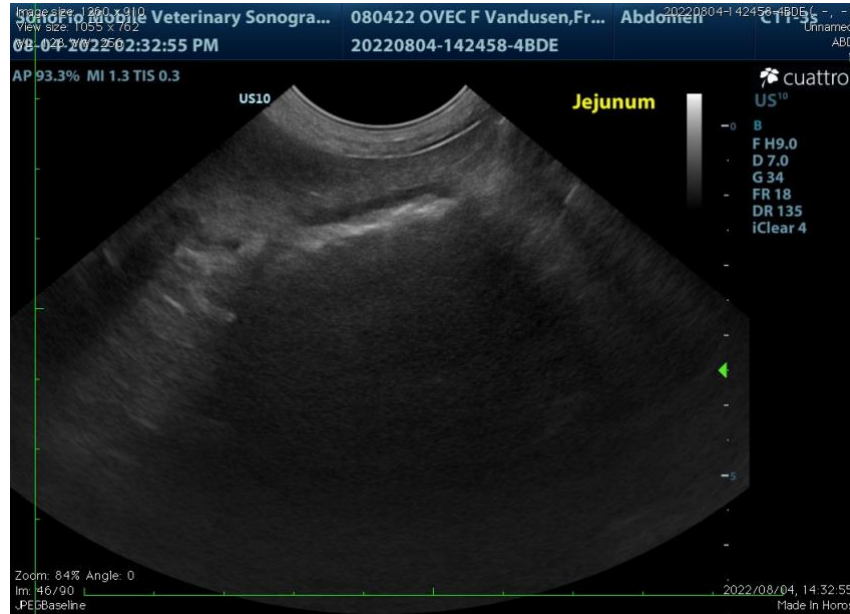
**SEX**

MN

**Age**

8 years

**WEIGHT**



**INTERPRETED BY**

Remo Lobetti, BVSc,  
 MMedVet (Med), PhD, Dipl.  
 ECVIM

**IMAGING PERFORMED BY**

Sonya Myers, DVM

**HOSPITAL NAME**

Oviedo Veterinary Care and  
 Emergency

**REFERRING VET**

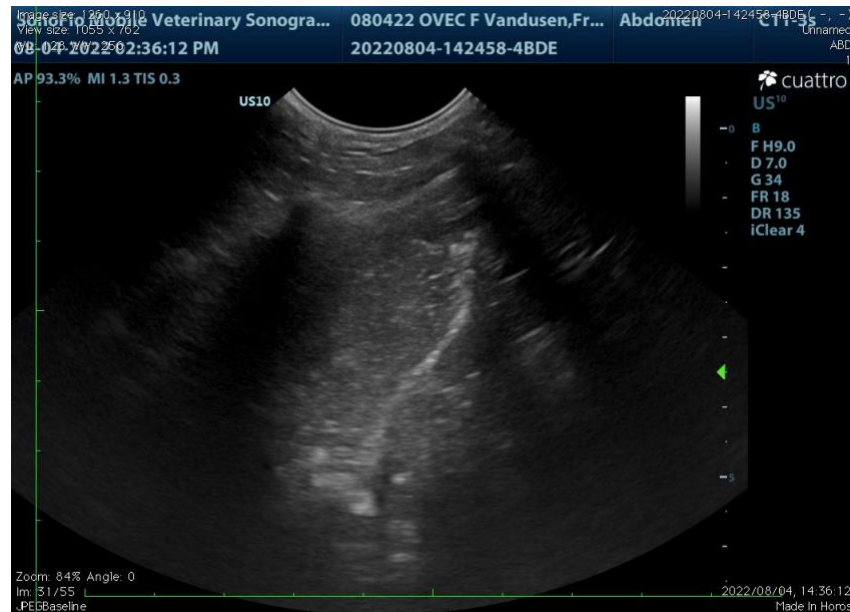
Dr Kim

**INVOICE**

303172

**DATE**

8/5/22





**PATIENT Stomach**

French Fry Vandusen

**SPECIES**

Canine

**BREED**

Miniature Schnauzer

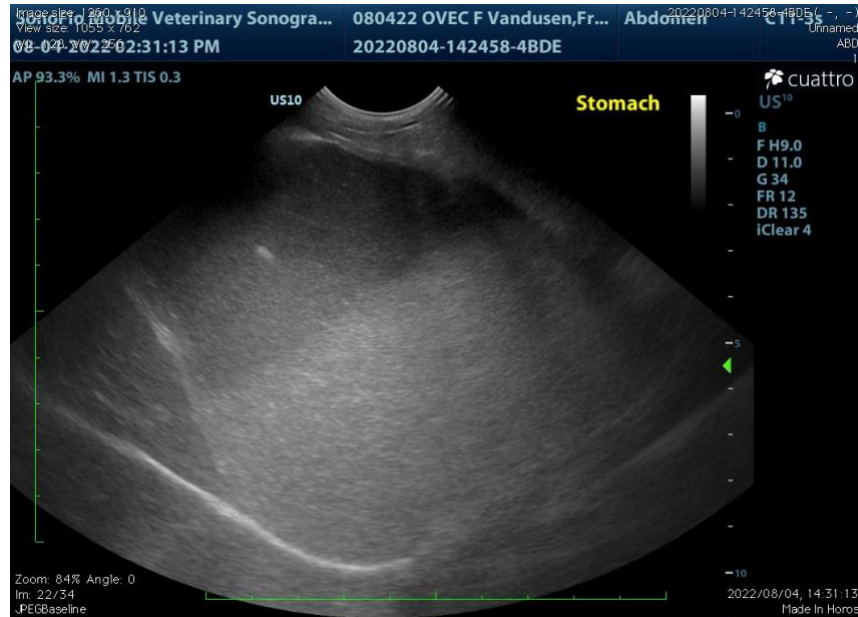**SEX**

MN

**Age**

8 years

**WEIGHT**



**INTERPRETED BY**

Remo Lobetti, BVSc,  
 MMedVet (Med), PhD, Dipl.  
 ECVIM

The information and recommendations provided are based on the images presented by the referring veterinarian. No evaluation can be communicated regarding pathology that was not visible in the image/video clips provided.

Thank you for this referral. If the clinical or image interpretation does not parallel your findings or if I can be of any further assistance, please contact me.

**IMAGING PERFORMED BY**

Sonya Myers, DVM

**Remo Lobetti, BVSc, MMedVet (Med), PhD, Dipl. ECVIM (Internal Medicine)**  
[robetti@mweb.co.za](mailto:robetti@mweb.co.za)

**HOSPITAL NAME**

Oviedo Veterinary Care and  
 Emergency

**REFERRING VET**

Dr Kim

**INVOICE**

303172

**DATE**

8/5/22